



Contents lists available at ScienceDirect

Journal of Hand Surgery Global Online

journal homepage: [www.JHSGO.org](http://www.JHSGO.org)

Original Research

## Threaded Pin and Volar Plate Fixation of Distal Radius Fractures: Early Functional Recovery



Justin Vaida, MD, \* Patrick M. Luchini, MD, \* Julie E. Glener, MD, \* Michael W. Kessler, MD, †  
Lucy A. McCabe, BS, ‡ John S. Taras, MD \*

\* Department of Orthopaedics, West Virginia University, Morgantown, WV

† Department of Orthopaedic Surgery, MedStar Georgetown University Hospital, Washington, DC

‡ Union Surgical, Doylestown, PA

### ARTICLE INFO

#### Article history:

Received for publication March 17, 2021

Accepted in revised form May 26, 2021

Available online June 27, 2021

#### Key words:

Distal radius fracture

Threaded pin

**Purpose:** To assess the results of threaded pin fixation and volar plate fixation of extra-articular distal radius fractures.

**Methods:** A retrospective case comparison study of patients undergoing operative fixation of distal radius fracture and postoperative therapy at 1 hand clinic was performed. Clinical variables included implant type along with the assessment of the volar tilt; radial height; postoperative wrist flexion, extension, pronation, and supination; key pinch; and grip strength. The duration of postoperative hand therapy was recorded. An independent Student *t* test was used to compare the 2 groups.

**Results:** Forty-three patients were identified (21 threaded pin and 22 volar plate). The mean ages were 46 years and 54 years for the threaded pin and the volar plate groups, respectively. Preoperative and postoperative radiographic parameters were similar for both the groups. No loss of reduction was observed. There were no statistically significant differences for postoperative range of motion or pinch and grip strength at the time of discharge from therapy. The threaded pin group had a mean duration of 65 days of therapy, and the volar plate group had a mean duration of 132 days of therapy.

**Conclusions:** Both groups achieved equivalent range of motion and functional recovery; however, the threaded pin group required significantly less therapy than the volar plate group. At the time of discharge from therapy, radiographic and clinical outcomes were similar for both types of implants, but the patients treated with a threaded pin required significantly less therapy and were discharged from therapy an average of 67 days sooner than the patients undergoing volar plate fixation.

**Type of study/level of evidence:** Therapeutic IV.

Copyright © 2021, THE AUTHORS. Published by Elsevier Inc. on behalf of The American Society for Surgery of the Hand. This is an open access article under the CC BY-NC-ND license (<http://creativecommons.org/licenses/by-nc-nd/4.0/>).

Open reduction and internal fixation of distal radius fractures (DRFs) has gained popularity during the last decade because of its ability to maintain reduction and tolerate the stress of an early wrist motion program, which has been associated with earlier functional recovery.<sup>1</sup> A review of orthopedic surgeons found that compared with percutaneous treatment, the percentage of DRFs

treated with open reduction and internal fixation rose from 42% in 1999 to 81% in 2007.<sup>2</sup> One reason for the popularity of this treatment is the increasing emphasis on minimizing postoperative immobilization.<sup>3</sup>

Implant options include variations in dorsal and volar plates, intramedullary devices, fragment-specific fixation plates, threaded pins, and combinations of these devices. The volar locking plate has become the most commonly used internal fixation device for DRF fixation.<sup>1,4–7</sup> All of these implants can accomplish the goals of restoring anatomy, range of motion (ROM), and function. However, complications such as tendon irritation, tenosynovitis, attrition, and rupture requiring plate removal have been reported.<sup>8–12</sup>

Taras et al<sup>13</sup> described a minimally invasive approach to stabilize extra-articular DRFs using threaded pins. Advantages of the

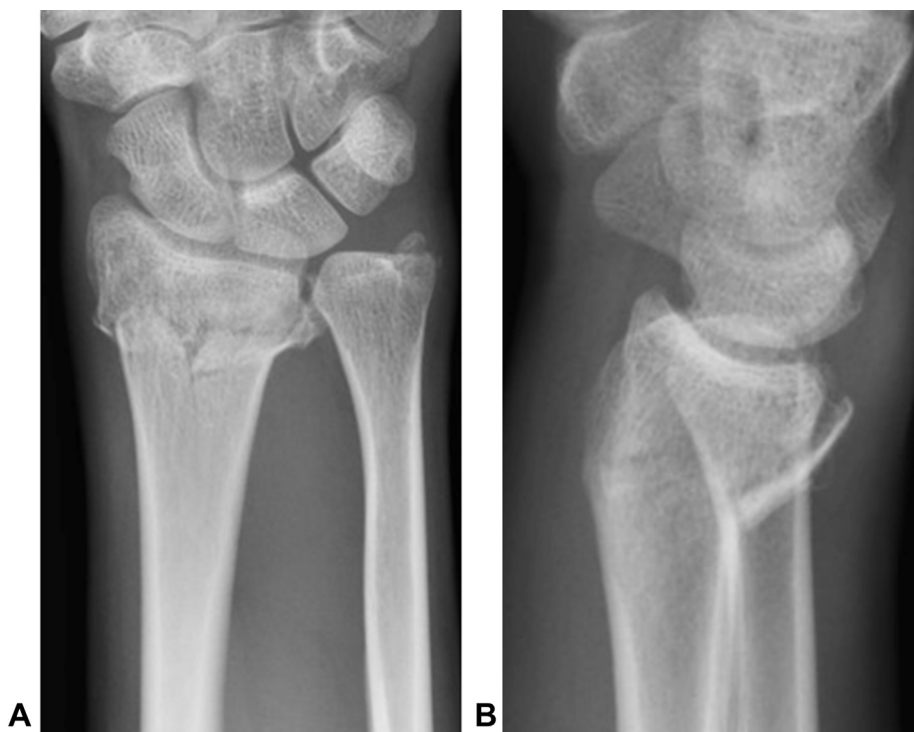**Declaration of interests:** Author McCabe is a consultant for Union Surgical LLC, and Dr Taras reports financial involvement with Union Surgical LLC. No benefits in any form have been received or will be received by the other authors related directly or indirectly to the subject of this article.

**Corresponding author:** John S. Taras, MD, Department of Orthopaedics, West Virginia University, PO Box 9196, Morgantown, WV 26506-9196.

E-mail address: [john.taras@hsc.wvu.edu](mailto:john.taras@hsc.wvu.edu) (J.S. Taras).

<https://doi.org/10.1016/j.jhsg.2021.05.012>

2589-5141/Copyright © 2021, THE AUTHORS. Published by Elsevier Inc. on behalf of The American Society for Surgery of the Hand. This is an open access article under the CC BY-NC-ND license (<http://creativecommons.org/licenses/by-nc-nd/4.0/>).



**Figure 1. A, B** Preoperative radiographs of a distal radius fracture.

procedure include the small incision size, cost reduction, possible implantation using local anesthesia with sedation, utility in medically unstable patients, and the strength to withstand an early wrist active ROM program. The authors hypothesized that threaded pin fixation after DRF restores wrist function earlier than volar plate fixation. The primary outcome of interest in this study was the time from surgery until therapy discharge.

## Materials and Methods

This study received approval by the institutional review board of Thomas Jefferson University; the necessary informed and Health Insurance Portability and Accountability Act consents were obtained from each patient enrolled. Over a 20-month period, patients were identified by querying the diagnosis codes for DRF (S52.539A, S52.509A) and cross-referencing the location code of our group's hand therapy offices. Results from the query were then manually reviewed to locate the cases of extra-articular DRFs treated by any type of volar plate or threaded pin (T-Pin, Union Surgical).

Exclusion criteria included intra-articular DRF, extra-articular DRF with concomitant injuries or factors influencing compliance with the therapy protocol, nonsurgical cases, and cases repaired with other devices. Patients with a history of previous DRFs and cases of systemic arthritis were also excluded. Classification of fractures was determined by radiographs reviewed by both the treating surgeon and a radiologist. All fractures were extra-articular in this study. No nondisplaced intra-articular fractures were included.

The preoperative and postoperative volar tilt, radial height, and radial inclination were measured by both the treating surgeon and a radiologist using both preoperative and final radiographs, the latter of which were obtained at the time of therapy discharge. Patients in the threaded pin group underwent fracture fixation as described by Taras et al<sup>13</sup> (Figs. 1, 2), whereas patients in the volar plate group underwent open reduction and internal fixation as

described by Orbay.<sup>14</sup> The determination of which fixation method would be used was made by the treating surgeon. In the case of threaded pin fixation, either 2 radial styloid pins or 1 styloid with 1 dorsal ulnar pin were used, depending on the presence of dorsal comminution. All procedures were performed by fellowship-trained upper-extremity surgeons within 2 weeks of injury.

All patients received hand therapy after surgery at the same hand therapy clinic by 1 of 3 certified hand therapists using the same physical therapy protocol. At 1–3 days after surgery, both groups were enrolled in a hand therapy program, which included edema control, digital ROM, and wrist ROM from 30° of flexion to 30° of extension for the first 2 weeks. Wrist ROM was then allowed to progress as tolerated; strengthening was initiated at 4 weeks. Therapists recorded outcome data, including measurements of wrist flexion, extension, pronation, and supination and pinch and grip strength in the affected extremity. A pinch dynamometer was used to gauge key pinch strength, and a Jamar dynamometer was used for grip strength, corrected for dominance. Criteria for discharge from therapy were achieving 70% to 80% of normal wrist ROM and normal grip strength. In some cases, discharge criteria were adapted to a patient's professional/personal requirements and expectations. The time from surgery to therapy discharge was recorded (Table). The patients were additionally observed for complications, defined as surgical site infection, tendon irritation, loss of reduction, or hardware migration or failure. A *P* value of <.05 was considered statistically significant.

## Results

The study cohort comprised 44 fractures in 43 patients (9 men and 35 women). Of these, 22 fractures were treated with 2 threaded pins (6 men and 15 women) and 22 fractures (3 men and 19 women) were treated with a volar locking plate. Each patient was treated with the operative fixation method determined before surgery, and no case required a deviation from the preoperative

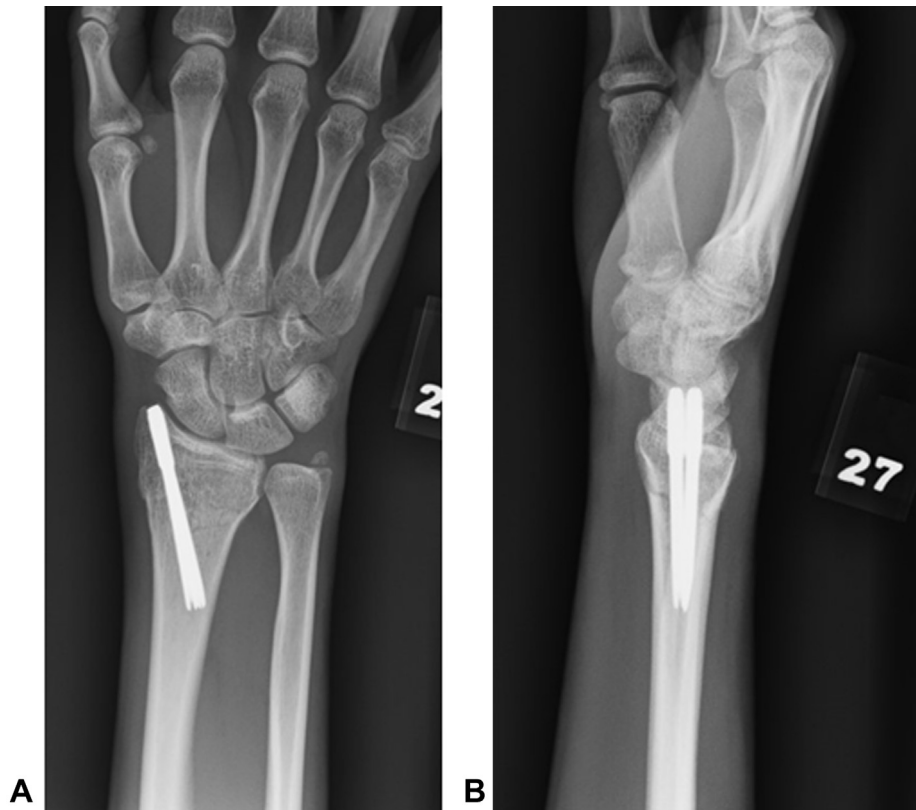


Figure 2. A, B Postoperative radiographs of a distal radius fracture with threaded pin fixation.

Table  
Study Results

Variable	Threaded Pin	Volar Plate	P Value
Subjects	21	21	
Sex, % female	71.4%	85.7%	.454
Age, y	46.3 ± 18.3	53.7 ± 16.7	.170
Preoperative volar tilt	-20.1° ± 14.0°	-19.1° ± 15.7°	.822
Postoperative volar tilt	5.1° ± 5.6°	7.0° ± 7.0°	.322
Preoperative radial height	6.8° ± 6.0°	5.2° ± 6.9°	.422
Postoperative radial height	9.8° ± 2.4°	9.0° ± 1.8°	.231
Therapy visits	10.8 ± 7.9	17.2 ± 10.9	.034
Therapy duration, d	65.3 ± 45.6	132.0 ± 136.7	.046*
Flexion	60.7° ± 19.4°	52.6° ± 11.6°	.116
Extension	59.4° ± 14.3°	58.2° ± 10.1°	.796
Pronation	82.9° ± 10.8°	78.7° ± 8.3°	.173
Supination	78.3° ± 18.5°	74.8° ± 10.9°	.464
Key pinch, kg	5.35 ± 2.86	5.6 ± 1.6	.752
Grip strength, kg	21.7 ± 14.0	15.2 ± 6.6	.170

\* Statistical significance.

plan. The average patient age was 46 years (range, 19–85 years) in the threaded pin group and 54 years (range, 16–79 years) in the volar plate group ( $P = .17$ ). Study cohort demographics are summarized in the Table. No statistical differences were found between the 2 groups.

The average preoperative radiographic volar tilt was  $-20^\circ$  in the threaded pin group and  $-19^\circ$  in the volar plate group ( $P = .82$ ). The postoperative volar tilts, measured at the time of discharge from therapy, were  $5^\circ$  and  $7^\circ$  in the threaded pin and volar plate groups, respectively ( $P = .33$ ). The preoperative radial height was 7 mm in the threaded pin group and 5 mm in the volar plate group ( $P = .44$ ). The postoperative heights measured 10 mm and 9 mm in the threaded pin and volar plate groups, respectively ( $P = .23$ ).

Patients were followed from the time of surgery until discharge from therapy. The mean therapy durations of the threaded pin and volar plate groups were 65 days (range, 1–167 days) and 132 days (range, 1–588 days;  $P = .05$ ), respectively. The groups were similar in terms of postoperative wrist flexion, extension, pronation, supination, and pinch or grip strength at the time of discharge from therapy. No patients experienced any of the previously defined complications, including loss of reduction.

A post hoc power analysis, given the study findings of an average difference of 67 days of physical therapy, shows a power of 53%, consistent with our significance finding. To achieve 80% power would require an average difference of 93 days of physical therapy.

### Discussion

The most notable finding of this study is the reduction in postoperative therapy duration for patients undergoing threaded pin fixation compared with those undergoing volar plating. These patients required an average of 67 fewer days of therapy, a reduction of 50.8%, to achieve the same functional outcomes. Further, when comparing the radiographic outcomes of the 2 treatment groups, there were no significant differences in postoperative volar tilt, radial height, or radial inclination. Moreover, the 2 groups were similar with respect to wrist ROM and grip and pinch strength at discharge from therapy. Ultimately, this study found that threaded pin fixation, when used in the appropriate patient, is as effective as volar plate fixation when treating extra-articular DRFs, achieving the same radiographic and functional outcomes with the benefits of requiring less therapy and of a more rapid discharge.

In review of the results, 2 subjects in the volar plate group appeared to be outliers, requiring prolonged therapy of 444 and 588 days. A subsequent analysis of the data after eliminating these

subjects yielded a similar range in the volar plate (1–217 days) and the threaded pin (1–167 days) groups. However, the respective average durations of therapy were 94 days and 65 days in the threaded pin and volar plate groups, respectively; thus, the threaded pin patients had 29 fewer days of therapy (31% less therapy). A 2-tailed test yielded a *P* value of .08; however, a 1-tailed test still yielded a significantly shorter duration of therapy (*P* = .04), consistent with our expectation of a reduction in the therapy duration.

Volar locking plates gained popularity over dorsal plate fixation due, in part, to the postoperative complications associated with the latter, including capsular contracture, extensor tendon tenosynovitis, attrition, and rupture, often necessitating additional corrective surgery.<sup>7–12</sup> Despite improved results with volar plating, these implants are not free from complications. Interference with soft tissues of the volar and dorsal wrist compartments are well documented, including attrition and rupture of flexor tendons and reports of extensor tendon rupture because of dorsal penetration of screws.<sup>15</sup>

For a typical Colles' fracture, 2 specialized threaded pins can be used to provide fracture fixation. Stabilization of these extra-articular DRFs with threaded pins provides the benefit of minimal soft tissue disruption and early active ROM. Additionally, the small insertion site enables the use of local anesthesia, making the implant an ideal treatment modality for both medically unstable and elderly patients who have sustained a DRF requiring operative intervention. In this study, surgeons used either sedation or general anesthesia, depending on the provider preference and patient-specific factors, with most pinning performed under local, monitored anesthesia care.

The current study's observed reduction in the total number of therapy visits and length of time until discharge from therapy is likely due to the minimally invasive properties of the threaded pin compared with the volar plate. While potential complications of the threaded pin include infection, pin migration, nerve irritation, and tendon rupture, none of the patients included in this study reported any of these complications.

At our institution, the most commonly used volar distal radius plates are the APTUS (MedArtis) and Geminus (Skeletal Dynamics), which cost approximately \$1236 and \$1156, respectively, including a typical configuration of screws. The cost of a standard threaded pin configuration at our institution is \$580. The treatment of extra-articular DRFs with threaded pins can cut the implant expense in half when compared to the volar plate.

There are several limitations to this study. While there were 2 concurrent treatment groups, patients were not randomized but rather fixed with whichever implant the treating surgeon deemed appropriate, introducing potential selection bias. Further, therapists were not blinded to the patient treatment group, and while the same minimum criteria for discharge was applied to both groups, a patient's discharge from therapy may be more subjective than outcomes used for a different study format. Additionally, a small number of patients in each group elected not to complete the

recommended therapy. While patient-reported outcome measures such as the Disabilities of the Arm, Shoulder and Hand questionnaire, Patient-Rated Wrist Evaluation, and Michigan Hand Questionnaire exist, there is no widely accepted objective standard by which to assess wrist function following a DRF, making it difficult to compare the results of this study with those of other trials.<sup>4</sup> Also, this study investigated patients with extra-articular DRFs, which makes comparison to studies with broader fracture pattern inclusion criteria difficult.

In conclusion, this study demonstrated that patients with extra-articular DRFs treated with threaded pins achieved similar radiographic and functional outcomes compared to patients treated with volar locking plates, while recovering significantly more quickly and requiring less postoperative hand therapy. In the appropriately selected patient, threaded pins provide a less invasive, lower cost fixation method, enabling a significantly reduced recovery period.

## References

1. Rozental TD, Blazar PE, Franko OI, Chacko AT, Earp BE, Day CS. Functional outcomes for unstable distal radial fractures treated with open reduction and internal fixation or closed reduction and percutaneous fixation. A prospective randomized trial. *J Bone Joint Surg Am.* 2009;91(8):1837–1846.
2. Koval KJ, Harrast JJ, Anglen JO, Weinstein JN. Fractures of the distal part of the radius. The evolution of practice over time. Where's the evidence? *J Bone Joint Surg Am.* 2008;90(9):1855–1861.
3. Benson LS, Minihane KP, Stern LD, Eller E, Seshadri R. The outcome of intra-articular distal radius fractures treated with fragment-specific fixation. *J Hand Surg Am.* 2006;31(8):1333–1339.
4. Ritting AW, Wolf JM. How to measure outcomes of distal radius fracture treatment. *Hand Clin.* 2012;28(2):165–175.
5. Wilcke MK, Abbaszadegan H, Adolphson PY. Wrist function recovers more rapidly after volar locked plating than after external fixation but the outcomes are similar after 1 year. *Acta Orthop.* 2011;82(1):76–81.
6. McFadyen I, Field J, McCann P, Ward J, Nicol S, Curwen C. Should unstable extra-articular distal radial fractures be treated with fixed-angle volar-locked plates or percutaneous Kirschner wires? A prospective randomised controlled trial. *Injury.* 2011;42(2):162–166.
7. Rozental TD, Blazar PE. Functional outcome and complications after volar plating for dorsally displaced, unstable fractures of the distal radius. *J Hand Surg Am.* 2006;31(3):359–365.
8. Ilyas AM, Thoder JJ. Intramedullary fixation of displaced distal radius fractures: a preliminary report. *J Hand Surg Am.* 2008;33(10):1706–1715.
9. Klitscher D, Mehling I, Nowak L, Nowak T, Rommens PM, Müller LP. Biomechanical comparison of dorsal nail plate versus screw and K-wire construct for extra-articular distal radius fractures in a cadaver bone model. *J Hand Surg Am.* 2010;35(4):611–618.
10. Simic PM, Robison J, Gardner MJ, Gelberman RH, Weiland AJ, Boyer MI. Treatment of distal radius fractures with a low-profile dorsal plating system: an outcomes assessment. *J Hand Surg Am.* 2006;31(3):382–386.
11. Ruch DS, Papadonikolakis A. Volar versus dorsal plating in the management of intra-articular distal radius fractures. *J Hand Surg Am.* 2006;31(1):9–16.
12. Kamath AF, Zurakowski D, Day CS. Low-profile dorsal plating for dorsally angulated distal radius fractures: an outcomes study. *J Hand Surg Am.* 2006;31(7):1061–1067.
13. Taras JS, Zambito KL, Abzug JM. T-pin for distal radius fracture. *Tech Hand Up Extrem Surg.* 2006;10(1):2–7.
14. Orbay J. Volar plate fixation of distal radius fractures. *Hand Clin.* 2005;21(3):347–354.
15. Sato K, Murakami K, Mimata Y, Doita M. Incidence of tendon rupture following volar plate fixation of distal radius fractures: a survey of 2787 cases. *J Orthop.* 2018;15(1):236–238.